

# Treatment of temporomandibular joint ankylosis by arthroplasty and mandibular distraction in children: our protocol of treatment

## *Tratamento de anquilose da articulação temporomandibular por artroplastia e distração mandibular em crianças: nosso protocolo de tratamento*

EMMANUELA NADAL LÓPEZ<sup>1</sup>, PEDRO LUIS DOGLIOTTI<sup>2</sup>, MARIANA SABAS<sup>3</sup>

### RESUMO

Anquilose da articulação temporomandibular (ATM) em crianças não afeta somente o crescimento mandibular, mas também o desenvolvimento do esqueleto facial. O enxerto costochondral tem sido usado para assegurar crescimento, mas este é imprevisível. Nós avaliamos, retrospectivamente, 27 pacientes submetidos a reconstrução de ATM por artroplastia. A etiologia foi séptica em 59,2% dos casos. O seguimento foi de, pelo menos, 12 meses em todos os casos. Artroplastia foi um procedimento rápido e fácil, com reduzidos tempo operatório, risco de transfusão de sangue, permanência hospitalar e custos. Mostrou, também, baixo risco de reanquilose. Além disso, foi associado a menor morbidade e complicações secundárias. Tomografia computadorizada mostrou um neocôndilo remodelado ao nível mandibular proximal. Ao exame clínico, os pacientes apresentavam graus variáveis de deformidade facial, e um potencial de crescimento mandibular desconhecido após artroplastia da ATM. Observamos, também, melhora clínica e do aspecto radiológico após correção da anquilose. É razoável realizar o tratamento da anquilose e distração mandibular simultaneamente, sem conhecimento de quanto os pacientes poderão crescer com o passar do tempo? Neste caso seria necessária uma predição de crescimento para realizar adequadamente a distração mandibular para obter resultados estáveis. O momento de realização da distração mandibular, após artroplastia da ATM e restauração da função mandibular, deve ser específico para a necessidade de cada paciente, assegurando as melhores condições e planejamento. Nós apresentamos nosso protocolo de tratamento incluindo: artroplastia da ATM com interposição de músculo temporal, e distração osteogênica mandibular, como um procedimento secundário, para corrigir retrognatismo e/ou assimetria, se necessário.

**Descritores:** Articulação temporomandibular. Anquilose. Criança. Artroplastia.

### SUMMARY

Temporomandibular joint (TMJ) ankylosis in children disturbs not only mandibular growth, but also facial skeletal development. Costochondral graft was used to ensure growth, but it had proven to be unpredictable. We evaluate, retrospectively, 27 patients who underwent TMJ reconstruction by arthroplasty. Etiology was septic in 59.2% of our cases. Follow up was at least 12 months in all cases. Arthroplasty was a quick and easy procedure, with reduced operating time, risk of blood transfusion, and hospital stays and costs. It also showed low risk of reankylosis. Furthermore, it was associated to a minor morbidity and secondary complications. Coronal computed tomography showed a remodeled neocondyle at the level of proximal mandibular end. On clinical examination patients had variable degree of facial deformity, and an unknown potential of mandibular growth after TMJ arthroplasty. We also observed improved clinical and radiological appearance after ankylosis correction. Is it reasonable to perform ankylosis release and mandibular distraction simultaneously without knowing which patients will be able to growth over time? In that case it would be necessary a growth prediction to apply the exactly amount of mandibular distraction to obtain stable results. Timing of mandibular distraction, after TMJ arthroplasty performed and mandibular function restored, must be specific to each patient's needs, assuring the best distraction conditions and planning. We present our treatment protocol including: TMJ joint arthroplasty with temporal muscle interposition, and mandibular distraction osteogenesis, as a secondary procedure, to correct retrognathism and/or asymmetry if necessary.

**Descriptors:** Temporomandibular joint. Ankylosis. Child. Arthroplasty.

1.MD, Department of Plastic Surgery and Burn Unit, Hospital de Pediatría SAMIC Prof. Dr. Juan P. Garrahan, Buenos Aires, Argentina.  
2.MD, Department of Plastic Surgery and Burn Unit, Hospital de Pediatría SAMIC Prof. Dr. Juan P. Garrahan, Buenos Aires, Argentina.  
3.DMD, Department of Plastic Surgery and Burn Unit, Hospital de Pediatría SAMIC Prof. Dr. Juan P. Garrahan, Buenos Aires, Argentina.

Correspondência: Dra. Emmanuela Nadal López  
Fray Justo Santa Mª de Oro 2976, 5B 1425 Buenos Aires, Argentina.  
E-mail: enadal@fibertel.com.ar

## INTRODUÇÃO

The term temporomandibular ankylosis refers to bone or fibrous adhesion of the anatomic joint components and the resulting loss of function<sup>1</sup>. A variety of techniques have been described in the literature for treatment of the temporomandibular joint (TMJ) ankylosis. However, no single method has produced uniformly successful results, limited range of motion and reankylosis are the most frequently reported complications<sup>2</sup>. In children ankylosis of the TMJ not only prevents mouth opening and chewing, but also affects the growth and position of the mandible, producing progressive facial distortion<sup>3</sup>. Since first use of costochondral graft to replace TMJ ankylosis reported by Gillies, in 1920<sup>4</sup>, several authors have proposed its use in children in order to catch up normal facial growth, but they have proven to produce unpredictable growth pattern<sup>5-9</sup>.

In this paper, we evaluate, retrospectively, the results obtained with TMJ arthroplasty in the treatment of TMJ ankylosis in children, avoiding the use of costochondral grafts. Our treatment plan includes: TMJ arthroplasty with temporal fascia interposition, and mandibular distraction osteogenesis, as a secondary procedure, to correct retrognathism and/or residual asymmetry, according our treatment protocol.

## METHOD

A retrospective study was conducted on patients who undergone TMJ reconstruction by unilateral or bilateral arthroplasty at the National Pediatric Hospital "Prof. Dr. Juan P. Garrahan", between 1998 and 2004. Patients included in the evaluation presented unilateral or bilateral bone TMJ ankylosis observed by coronal CT scan, they had never received treatment, preoperative maximal interincisal opening was less than 10 mm, and follow up was at least of one year. In this group of treatment, we evaluated: age, sex, etiology, unilateral/bilateral involvement, operating time, need of blood transfusion and intensive postoperative care, days of hospitalization, and complications related to the surgical procedure. We performed computed tomographic scan pre and postoperatively to evaluate changes at TMJ level. After reestablishing mouth opening, we observed a great variability in mandibular growth during follow-up, and depending on the patient age, the presence of upper airway obstruction (obstructive sleep apnea syndrome or tracheostomy dependent patients), and the severity of mandibular and facial growth restriction, we established a protocol of treatment.

## RESULTS

During the last six years, we have treated twenty seven cases of TMJ ankylosis (seventeen males and ten females). Patient ages ranged from 1 year 6 month to 17 (average 6 years 1 month). Bilateral TMJ ankylosis was observed in 9 cases. Etiopathogenesis was septic in 17 cases, congenital in 8 cases, traumatic in 2.

All patients underwent surgical treatment by TMJ

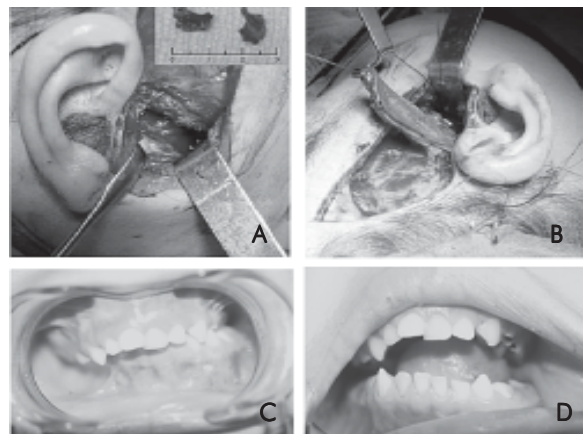
arthroplasty (nine of them bilaterally). Follow up was at least 12 months in all cases.

We exposed the zygomatic arch and the TMJ to perform an arthroplasty using a preauricular incision, avoiding injury of the facial nerve. After identification of the site of ankylosis, we performed an osteotomy with a thin osteotome below the zygomatic arch, dividing the bone at the glenoid fossa. Then, a coronoidectomy, and subperiosteal stripping of muscles (temporalis, masseter, and medial pterygoid) were performed on the ipsilateral side as far as possible. After joint released, the jaw was swung anteriorly and laterally, and a gap appeared at TMJ level. If minimal interincisal opening was less than 30 millimeters without the use of force, a contralateral coronoidectomy was performed via an intraoral approach. After optimal interincisal opening, the joint was reconstructed. The proximal end of the mandibular ramus and the glenoid fossa were recontoured, removing a minimal quantity of bone. The TMJ was lined with a temporalis muscular flap pedicled inferiorly on the medial temporal artery and rotated over the arch into the joint. The flap was sutured to the recipient bed with 4-0 Vicryl an intraoperative splint with an ipsilateral posterior open bite was constructed to compensate the occlusion, and to maintain the gap (Figure 1).

Operating time in this group ranged from 1 hour 45 minutes to 2 hours 30 minutes, averaging 1.8 hours each TMJ treated, we performed thirty six arthroplasty procedures. One patient treated by bilateral arthroplasty needed blood transfusion during surgery. And another needed intensive postoperative care due to a cardiac arrhythmia. Days of hospitalization ranged from 1 to 7 days (mean time 2.8 days). Postoperative maximal interincisal opening ranged from 29 to 35 mm (mean 31.1 mm).

Postoperative complications were one floor mouth infection due to circumferential wires, and six patients

**Figure 1** – A. Gap observed at TMJ level after mandibular release. B. Temporal flap was rotated over the arch into the joint and sutured to the recipient bed. C. Presurgical intraoral view. D. Intraoperative view of mandibular swung after TMJ release



presented reankylosis, four of the were bilateral cases, which represented 22% of recurrence of ankylosis in this group of treatment. We have observed an improved clinical appearance after TMJ arthroplasty (Figure 2). CT scan revealed a remodeled proximal mandibular end postoperatively (Figure 3).

At first consultation, three patients presented upper airway obstruction (one was a tracheostomy dependent and two suffered obstructive sleep apnea syndrome) due to severe microretrognathia. In these three cases, we performed a bilateral mandibular distraction as the first procedure. At the moment of device removal, we performed bilateral

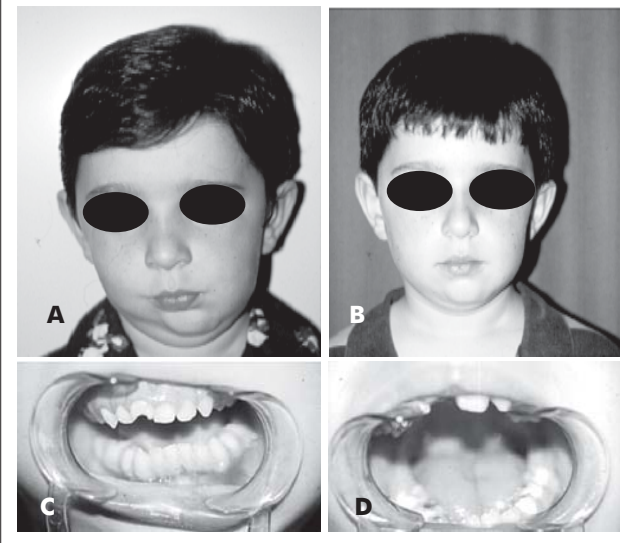
arthroplasty (Figure 4). The other cases (six bilateral TMJ ankylosis and 18 unilateral TMJ ankylosis) were treated by unilateral or bilateral arthroplasty as the first procedure. Two bilateral cases presented upper airway obstruction as severe obstructive sleep apnea syndrome during follow up, and we performed a bilateral mandibular distraction to avoid tracheostomy. Three patients with unilateral affection presented mandibular asymmetry which was corrected by unilateral mandibular distraction.

## DISCUSSION

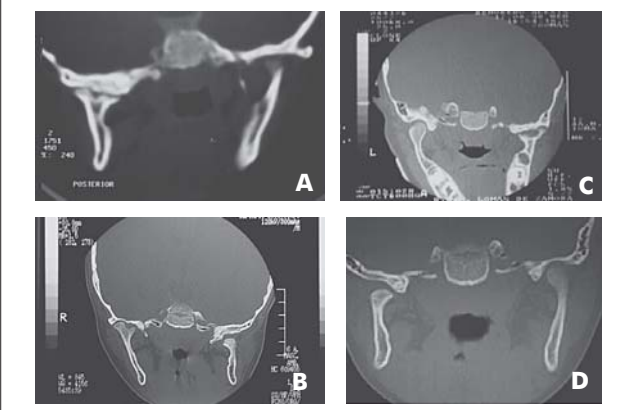
There are compelling fundamental reasons for constructing a TMJ if ankylosis is present. Failure to alleviate the ankylosis can result in speech impairment, difficulties with mastication, poor oral hygiene, rampant caries, facial and mandibular growth disturbances and acute airway compromise<sup>10</sup>.

The causes of TMJ ankylosis can be diverse. Trauma and particularly mandibular condyle fracture represent the most frequent cause, with a frequency reported between 29 and 100%<sup>1</sup>. Etiopathogenesis was septic in 59.2% of

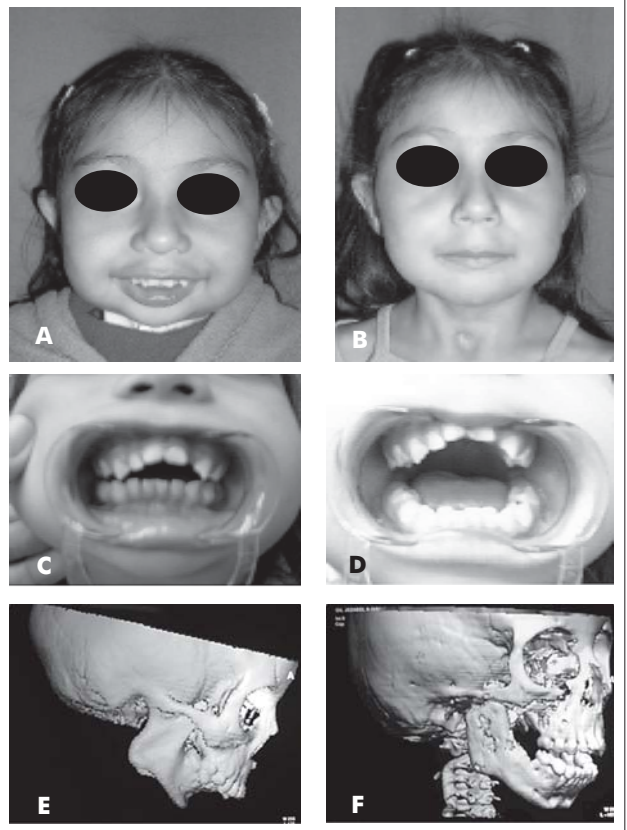
**Figure 2** – A. Initial appearance male patient of 5 years old with left TMJ ankylosis. B. Postoperative image of the patient two years and a half after left arthroplasty: we can observe improved clinical appearance. C. Functional limitation of mouth opening. D. Functional recovery of mouth opening two and a half years after arthroplasty



**Figure 3** – A and C. Computed tomographic scans show TMJ ankylosis in two different patients. B and D. After arthroplasty, the proximal mandibular ends remodel to form a neocondyle



**Figure 4** – A and B. Preoperative and one year and a half postoperative appearance of the patient affected by bilateral temporomandibular joint ankylosis and treated by bilateral mandibular distraction followed by bilateral arthroplasty. C and D. Pre and postoperative mouth opening. E and F. Pre and postoperative CT scan



our cases, perhaps due to poor sanitary conditions and lower mean age than in others groups reported.

Treatment of TMJ ankylosis in children poses a significant challenge to the plastic surgeon. It is due to high incidence of recurrence as well as unpredictability of bone growth. Poswillo<sup>11</sup> demonstrated the functional similarities between mandibular condyle and rib cartilage, showing that a costochondral graft can replace the condylar head. Since then several reports evaluated growth of costochondral graft. Guyuron e Lasa<sup>7</sup>, in 1992, concluded that the growth pattern of costochondral graft is extremely unpredictable, ankylosis is a common problem following a TMJ reconstruction with costochondral graft, and mandibular overgrowth on the grafted side can actually be more trouble than the lack of growth. Obeid et al.<sup>12</sup> cautioned that patients who are grafted during active growth might require additional corrective osteotomies, increasing patient's morbidity. Ross<sup>9</sup> showed that of 48 grafts, 17 (35%) costochondral grafts were lost or reankylosed, and these costochondral grafts in ankylosis reached a success rate of only 40%, while hemifacial microsomia cases had a 70% success rate. Although he pointed that it is extremely difficult to accurately monitor the long-term growth of costochondral grafts, identifying that some growth has occurred is not difficult, however precise amount of growth is virtually impossible to determine. In the successful group a 46% showed a growth clinically undetectable, 15% a deficiency in the growth of the grafts, and 39% demonstrated excessive growth.

In a previous report<sup>13</sup>, we observed that arthroplasty is a quicker and easier procedure than the costochondral graft, reducing operating time, risk of blood transfusion, and hospital stays and costs. It also shows less risk of reankylosis, 13% vs. 25%. In the group evaluated reankylosis is 22%, and we attribute the increase to bilateral cases, 33% in this series instead 25% in the mentioned paper. Furthermore, it is associated to a minor morbidity and secondary complications. A 75% of our patients treated with bone graft required additional secondary surgery. Arthroplasty has also the advantages of avoiding donor bone site morbidity, and the use of alloplastic materials as well as intermaxillary fixation.

After TMJ arthroplasty, at the level of proximal mandibular end we have observed radiographically a remodeled neocondyle seated in the glenoid fossa, similar of those observed by Stucki-McCormick<sup>14</sup> during reconstruction of the mandibular condyle using transport distraction osteogenesis. We agree with her that mandibular motions induced the functional remodeling of the proximal mandibular end to form neocondyles.

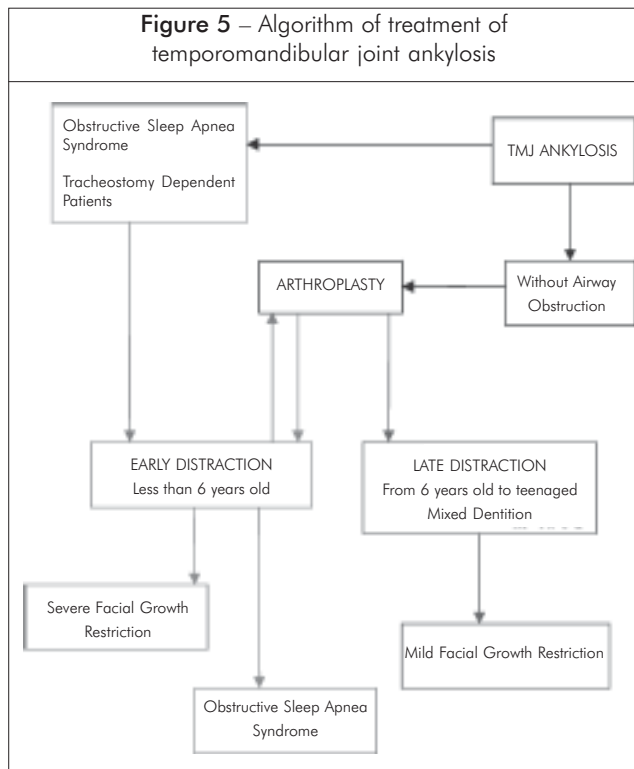
Whereas in adults the main objective of TMJ reconstruction is to restore lost function, in children we should deal also with growth. The process is more severe in youngest patients due to the consequences in maxillofacial skeletal growth. Growth impairment seems to be the result of: condylar destruction and lack of stimulus to the growth induced by mandibular function and movement. The younger the patients at the time of condylar

damage, and the longer the period of ankylosis before treatment, more severe will be the degree of deformity and more affected the external facial aspect<sup>15</sup>. But experimental attempts to extirpate condylar growth centers have been repeatedly unsuccessful, and clinical observations have been conflicting, and there is also good clinical evidence refuting the theory of the functional matrix. Thus, neither theory satisfactorily explains all details or clinical situations<sup>16</sup>. Our clinical observation showed patients who had the same age at the time of TMJ impairment showed variable grades of facial deformity, and they had different growth rate after TMJ surgical release by arthroplasty, even those who developed reankylosis showed different growth rate during long term follow-up.

Distraction osteogenesis has become a widely extended method to treat craniofacial malformations and it has proven to be effective in the treatment of mandibular hypoplasia<sup>17-21</sup>. However, there is no agreement on whether distraction must be performed at the time of arthroplasty. Meanwhile some authors prefer to perform the procedures simultaneously<sup>14,22-24</sup>, we recommend a two phases procedure because of recovery of mandibular function must be the main goal, and reankylosis is the complication most frequently reported. Postoperative physical therapy is essential in the treatment of TMJ ankylosis, and molding of the regenerate bone by intermaxillary elastic during active distraction and consolidation phase may interfere with it. There might be also increased risk of pseudoarthrosis at the osteotomy site due to strong physical therapy. Furthermore, these external forces may change the initial vector of distraction. Distraction is best performed after a detailed preoperative surgeon-orthodontist evaluation and development of a comprehensive treatment plan, and dental hygiene must be optimal<sup>25</sup>.

The challenge in these patients lies in the variable degree of mandibular hypoplasia, as well as restricted growth of associated facial structures preoperatively, and the unknown potential of growth of the mandible once TMJ ankylosis is liberated. We do not know how many of the patients treated by arthroplasty will be able to catch up normal growth over time. Timing of mandibular distraction, after TMJ arthroplasty, must be specific to the patient's needs, as suggested by Polley<sup>24</sup>.

We have two main groups of treatment of patients with TMJ ankylosis related to upper airway compromise. If the patient at the first clinical examination suffers sleep obstructive apnea syndrome or is tracheostomized, we will perform a mandibular distraction to solve the airway compromise or to close the tracheostoma, increasing body and ramus mandibular length, and converting the TMJ from a first level with de fulcrum in the region of the last molar to a third class lever with the fulcrum at the joint. In this group we do TMJ arthroplasty at the moment of removing distraction device. We do TMJ arthroplasty as first procedure in patients who do not have airway compromise. After this procedure we would find also two groups of treatment related to postoperative mandibular growth, similar to those proposed by McCarthy et al.<sup>26</sup> to address mandi-



bular deformity in hemifacial microsomia. Until 6 years old patients, we perform a distraction, after TMJ arthroplasty was done and mandibular function ensured, when children present with severe mandibular hypoplasia and restriction of related facial structures, or associated sleep apnea syndrome or tracheostomy. Warning that a secondary or even tertiary distraction may be required after post pubertal facial growth in some cases. In patients with minimal hypoplasia and facial deformity we perform distraction, if necessary, from 6 to teenaged years during the period of mixed dentition depending on clinical appearance and rate growth observed postoperatively, assuring the best distraction conditions and planning (Figure 5).

More accurately results of this treatment protocol will be the subject of the next paper as we will have follow up enough to evaluate mandibular growth and need of mandibular distraction, in a bigger group of patients treated by TMJ arthroplasty.

## REFERENCES

1. Valentini V, Vetrano S, Agrillo A, Torroni A, Fabiani F, Iannetti G. Surgical treatment of TMJ ankylosis: our experience (60 cases). *J Craniofac Surg.* 2002;13(1):59-67.
2. Kaban LB, Perrott DH, Fisher K. A protocol for management of temporomandibular joint ankylosis. *J Oral Maxillofac Surg.* 1990;48(11):1145-52.
3. Munro IR, Chen YR, Park BY. Simultaneous total correction of temporomandibular ankylosis and facial asymmetry. *Plast Reconstr Surg.* 1986;77(4):517-29.

4. Gillies HD. *Plastic surgery of the face.* London:Oxford University Press;1920.
5. Ware WH. Growth center transplantation in temporomandibular joint surgery. In: Walker RV, ed. *Oral surgery: Transactions of Third International Conference on Oral Surgery.* Edinburgh: E&S Livingstone;1970. p.148.
6. Ware WH, Brown SL. Growth center transplantation to replace mandibular condyles. *J Maxillofac Surg.* 1981;9(1):50-8.
7. Guyuron B, Lasa CI Jr. Unpredictable growth pattern of costochondral graft. *Plast Reconstr Surg.* 1992;90(5):880-9.
8. Perrott DH, Umeda H, Kaban LB. Costochondral grafts construction/reconstruction of the ramus/condyle unit: long-term follow-up. *Int J Oral Maxillofac Surg.* 1994;23(6 Pt 1):321-8.
9. Ross RB. Costochondral grafts replacing the mandibular condyle. *Cleft Palate Craniofac J.* 1999;36(4):334-9.
10. Posnick JC, Goldstein JA. Surgical management of temporomandibular joint ankylosis in the pediatric population. *Plast Reconstr Surg.* 1993;91(5):791-8.
11. Poswillo D. Experimental reconstruction of the mandibular joint. *Int J Oral Surg.* 1974;3(6):400-11.
12. Obeid G, Guttenberg SA, Connole PW. Costochondral grafting in condylar replacement and mandibular reconstruction. *J Oral Maxillofac Surg.* 1988;46(3):177-82.
13. Nadal E, Dogliotti PL. Treatment of temporomandibular joint ankylosis in children: is it necessary to perform mandibular distraction simultaneously? *J Craniofac Surg.* 2004;15(5):879-85.
14. Stucki-McCormick SU. Reconstruction of the mandibular condyle using transport distraction osteogenesis. *J Craniofac Surg.* 1997;8(1):48-53.
15. Dean A, Alamillos F. Mandibular distraction in temporomandibular joint ankylosis. *Plast Reconstr Surg.* 1999;104(7):2021-31.
16. Zins JE, Smith JD, James DR. Surgical correction of temporomandibular joint ankylosis. *Clin Plast Surg.* 1989;16(4):725-32.
17. McCarthy JG, Schreiber J, Karp N, Thorne CH, Grayson BH. Lengthening the human mandible by gradual distraction. *Plast Reconstr Surg.* 1992;89(1):1-8.
18. Moore MH, Guzman-Stein G, Proudman TW, Abbott AH, Netherway DJ, David DJ. Mandibular lengthening by distraction for airway obstruction in Treacher-Collins syndrome. *J Craniofac Surg.* 1994;5(1):22-5.
19. Molina F, Ortiz Monasterio F. Mandibular elongation and remodeling by distraction: a farewell to major osteotomies. *Plast Reconstr Surg.* 1995;96(4):825-42.
20. Rachmiel A, Levy M, Laufer D. Lengthening of the mandible by distraction osteogenesis: report of cases. *J Oral Maxillofac Surg.* 1995;53(7):838-46.
21. Pensler JM, Goldberg DP, Lindell B, Carroll NC. Skeletal distraction of the hypoplastic mandible. *Ann Plast Surg.* 1995;34(2):130-7.
22. Papageorge MB, Apostolidis C. Simultaneous mandibular distraction and arthroplasty in a patient with temporomandibular joint ankylosis and mandibular hypoplasia. *J Oral Maxillofac Surg.* 1999;57(3):328-33.
23. Alonso N, Freitas RS. Mandible distraction: comparison between internal and external applied devices. *Cir Plást Iberlatinamer.* 2002;28(3):195-200.
24. Cascone P, Agrillo A, Spuntarelli G. Combined surgical therapy of temporomandibular joint ankylosis and secondary deformity using intraoral distraction. *J Craniofac Surg.* 2002;13(3):401-10.
25. McCarthy JG, Katzen JT, Hopper R, Grayson BH. The first decade of mandibular distraction: lessons we have learned. *Plast Reconstr Surg.* 2002;110(7):1704-13.
26. McCarthy JG, Stelnicki EJ, Grayson BH. Distraction osteogenesis of the mandible: a ten-year experience. *Semin Orthod.* 1999;5(1):3-8.